Orthodontic Movement into Infrabony Defects in Patients with Advanced Periodontal Disease: A Clinical and Radiological Study

Giuseppe Corrente,* Roberto Abundo,* Stefania Re,* Daniele Cardaropoli,* and Giuseppe Cardaropoli†

Background: In cases of advanced periodontal disease with a pathologic flaring of frontal teeth, a combined periodontic-orthodontic therapy may be a reliable approach in order to solve both functional and esthetic problems. The aim of the present study was to evaluate the periodontal tissue alterations following periodontal surgery and orthodontic intrusion in migrated upper central incisors with intrabony defects.

Methods: Ten patients with advanced periodontal disease and an extruded maxillary central incisor infrabony defect at its mesial aspect and probing depth (PD) ≥6 mm were included in the present study. At baseline, PD and clinical attachment level (CAL) were measured. The vertical and horizontal dimensions of the defects were assessed on standardized radiographs. Seven to 10 days after surgery the active orthodontic treatment started using the segmented arch technique, in order to intrude and move the teeth into the defects. Maintenance therapy was performed every 2 to 3 months until the orthodontic treatment was completed.

Results: At the end of treatment, mean PD reduction was 4.35 mm, with a residual mean PD of 2.80 mm. Mean CAL gain was 5.50 mm. The mean radiological vertical and horizontal bone fills were, respectively, 1.35 mm and 1.40 mm. All differences were of statistical significance ($P<0.001$).

Conclusion: The present study showed that the combined orthodontic and periodontic therapy performed resulted in the realignment of extruded teeth with infrabony defects, obtaining a significant probing depth reduction, clinical attachment gain, and radiological bone fill. *J Periodontol 2003;74:1104-1109.*

KEY WORDS

Bone regeneration; follow-up studies; orthodontics, corrective; periodontal attachment; periodontal pockets/therapy; tooth mobility/prevention and control.

* Private practice, Turin, Italy.
† Faculty of Odontology, Göteborg University, Göteborg, Sweden.

The question of whether or not orthodontic movement may have negative effects on periodontal tissues, such as root resorption, pocket deepening, or attachment loss, has been evaluated in a number of investigations during the years. Three studies[1-3] showed that in dentitions with reduced periodontium, orthodontic forces and tooth movement do not induce damage of the periodontal tissues if good oral hygiene is provided, but in presence of plaque-induced inflammation, similar forces may cause a more rapid periodontal tissue breakdown.

Re et al., in a 12-year follow-up study on 276 patients, reported a long-term stability of adult periodontal patients following orthodontic-periodontic combined treatment.[4] In order to obtain good treatment results in patients with reduced periodontal support, the use of light and continuous orthodontic forces, together with the absence of gingival inflammation, are considered to be the most important factors. Melsen et al.[5,6] suggested, both in animal and clinical studies, that the combination of periodontal treatment and orthodontic intrusion may result in new attachment formation and clinical attachment gain if good oral hygiene could be maintained. An experimental study on teeth with infrabony pockets reported that, if complete elimination of subgingival infection is performed before orthodontic movement is

begun, no detrimental effect on the attachment level is observed.[7] In this study the angular bony defects were eliminated but no attachment gain was achieved.

Another experimental study[8] showed that tooth movement may enhance the rate of destruction of the connective tissue attachment at teeth with inflamed, infrabony pockets.

However, clinical studies that have examined the effect of orthodontic movement in periodontal patients with infrabony defects are limited and report different results.[9-13]

The aim of this clinical work was to evaluate the effect of a combined approach, including periodontal surgery and orthodontic intrusion, in treating 10 adult periodontal patients with infraosseous defects on extruded maxillary central incisors. A previous paper by the same authors[14] evaluated the results obtained from a more strictly orthodontic point of view, including clinical crown length, marginal bone level, and root apex modifications.

The present paper evaluates the clinical periodontal parameters including clinical attachment level and probing depth and of the radiological dimensions of the defects.

MATERIALS AND METHODS

Ten adult patients (8 female and 2 male, aged 33 to 53 years) were included in the present study. All patients were in good general health with no systemic diseases or drugs consumption during the previous 3 months. They were all treated for periodontal disease by means of scaling and root planing during initial therapy. The clinical inclusion criteria were: 1) migration of the maxillary frontal teeth with at least 1 mm of extrusion of one central incisor in respect to the incisal edge of the contralateral incisor; 2) radiological evidence of infrabony defect at the mesial aspect of the extruded incisor; 3) probing depth (PD) ≥6 mm at the defect site; and 4) plaque index (PI) ≤15%.[15] Four right and six left central incisors were included in the study. At baseline, PD and clinical attachment level (CAL) were assessed using a calibrated periodontal probe. Radiographs were obtained following the long-cone parallel technique and using film holders standardized by means of silicon impression material in order to increase the post-treatment reproducibility.[14] The vertical distance between the horizontal projection of the bone crest on the root surface (TD) and the most apical point of the bone defect (BD), and the horizontal distance from bone crest (BC) and TD were assessed on the radiographs using an operative microscope‡ at a 5× magnification (Fig. 1).

All patients received surgical therapy by means of open flap procedure. Following local anesthesia, full-thickness flaps were elevated, granulation tissue was removed, and scaling and root planing performed on the root surfaces.

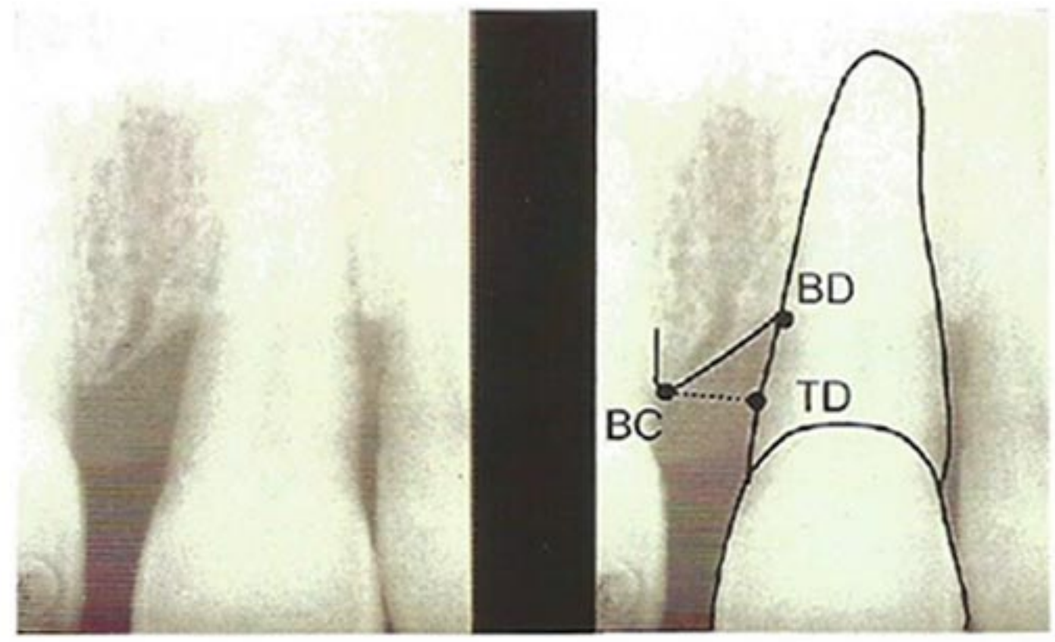

Figure 1.
Schematic drawing of the radiographic measurements. TD-BD: vertical dimension; BC-TD horizontal dimension of the infrabony defects.

At the intraoperatory examination, all defects were classified as 1-, 2-, or 3-wall infrabony defects. The flaps were closed and sutured with interrupted sutures. The patients rinsed twice a day with 0.2% chlorhexidine digluconate for 7 to 10 days. The sutures were removed 7 to 10 days after surgery and patients started mechanical cleaning. At that time, the active orthodontic treatment started following the segmented arch technique.[16,17] A biomechanical system made of intrusive arches and cantilevers was used to develop light (10 to 15 gr) and continuous forces in order to close spaces and to obtain intrusion of the pathologically extruded teeth. The posterior anchorage was obtained by means of palatal arches and stainless steel segments.

During the orthodontic treatment period, all patients were enrolled in a recall program with maintenance therapy including professional tooth cleaning every 2 to 3 months.[18,19] Orthodontic treatment lasted a mean time of 10 ± 2.6 months. At the end of the treatment period, all patients received permanent retention using Maryland fixed splints[20] in order to avoid orthodontic relapse and for better chewing comfort. At the same time clinical and radiographic parameters were measured (PD, CAL, TD-BD, and BC-TD).

The extent of intrusion was assessed in relation to the contralateral incisor edge by measurements on study model casts using a calibrated calliper.§

Both initial and final measurements were calculated using the mean values of two independent measurements, performed by two different clinicians, rounded to the nearest mm. Pre- and postoperative mean values and standard deviations were calculated. Differences were statistically analyzed by means of t test for coupled data. Values with $P<0.001$ were considered statistically significant.

‡ OPMI-ORL, Carl Zeiss, Oberkochen, Germany.
§ Model P1560-15, Leone, Florence, Italy.

RESULTS

Tables 1 and 2, respectively, show the individual clinical and radiological measurements with means values and standard deviations at baseline and at end of treatment.

Mean CAL gain was 5.50 ± 1.75 mm, while mean PD reduction was 4.35 ± 1.33 mm. At the end of the therapy, mean residual PD was 2.80 ± 0.42 mm.

The radiographic examinations showed a bone fill of 1.35 ± 0.75 mm on the vertical defect dimension and 1.40 ± 0.88 mm on the horizontal dimension. The average intrusion of the treated teeth was 2.1 ± 0.5 mm. The difference between pre- and post-treatment values of all the measured parameters was statistically significant ($P<0.001$). No negative effects due to orthodontic movement were observed on the treated teeth (i.e., root resorption, loss of pulp vitality, compensatory extrusion of the neighboring teeth).

DISCUSSION

This clinical study evaluated the possibility of performing orthodontic movement into infrabony defects of migrated incisors in patients with advanced periodontal disease. The combined therapy, consisting of open flap surgery and orthodontic intrusion, resulted in the realignment of the treated incisors (Figs. 2 and 4) with radiological bone fill (Figs. 3 and 5), CAL gain, and PD reduction. The residual PD <3 mm and the absence of bleeding on probing confirmed the possibility of achieving a healthy periodontal condition.

The positive results obtained in terms of shortening the clinical crown length, effecting intrusion, and increasing the marginal bone level, without a significant apex resorption were reported earlier on this same patient population.[14]

The goal of periodontal therapy is to stop disease progression and to regenerate the lost periodontal support. Over the years, open flap surgery, graft materials, and regenerative techniques have been used to achieve this goal in periodontal lesions with infrabony pockets.[21,22]

Advanced periodontal disease may result in periodontal lesions with intraosseous defects and extrusion of the upper incisors. In these situations, orthodontic treatment may be a reliable therapeutic approach to realign migrated teeth once periodontal therapy is performed.

However, there are only few studies and case reports regarding the use of orthodontic movement in treatment of pathologically migrated teeth with infrabony pockets.[9-14]

Animal studies have confirmed that orthodontic movement is not detrimental for periodontal tissues if plaque control is provided, but in presence of inflammation it can lead to further periodontal breakdown. Different

Table 2.

Initial and Final Values and Change in Radiological Vertical (TD-BD) and Horizontal (BC-TD) Dimension of Bone Defects (mm)

	TD-BD			BC-TD		
Patient	Initial	Final	Change	Initial	Final	Change
1	6.5	4.5	2	3	1.5	1.5
2	3.5	1	2.5	3.5	1.5	2
3	4	2.5	1.5	3	3	0
4	3	1.5	1.5	2.5	2	0.5
5	5	5	0	4	2.5	1.5
6	6	4	2	3.5	3	0.5
7	3.5	2	1.5	4	2	2
8	4.5	4	0.5	4	1.5	2.5
9	4	3	1	4.5	2	2.5
10	3	2	1	2	1	1
Mean ± SD	4.30 ± 1.21	2.95 ± 1.36	1.35 ± 0.75*	3.40 ± 0.77	2.00 ± 0.67	1.40 ± 0.88*

* Significant difference at $P<0.001$; t test for coupled data.

Table 1.

Initial and Final Values and Change in Clinical Attachment Level (CAL) and Probing Depth (PD) (mm)

	CAL			PD		
Patient	Initial	Final	Change	Initial	Final	Change
1	8	3	5	7	3	4
2	12.5	4	8.5	9.5	3	6.5
3	7	2.5	5.5	6	2	4
4	8	4	4	6	3	3
5	9	5	4	6	3	3
6	10	5	5	7	3	4
7	7	3	4	6	3	3
8	9.5	3	6.5	9	3	6
9	7	2	5	6	2	4
10	11.5	3	8.5	9	3	6
Mean ± SD	8.95 ± 1.94	3.45 ± 1.01	5.50 ± 1.75*	7.15 ± 1.45	2.80 ± 0.42	4.35 ± 1.33*

* Significant difference at $P<0.001$; t test for coupled data.

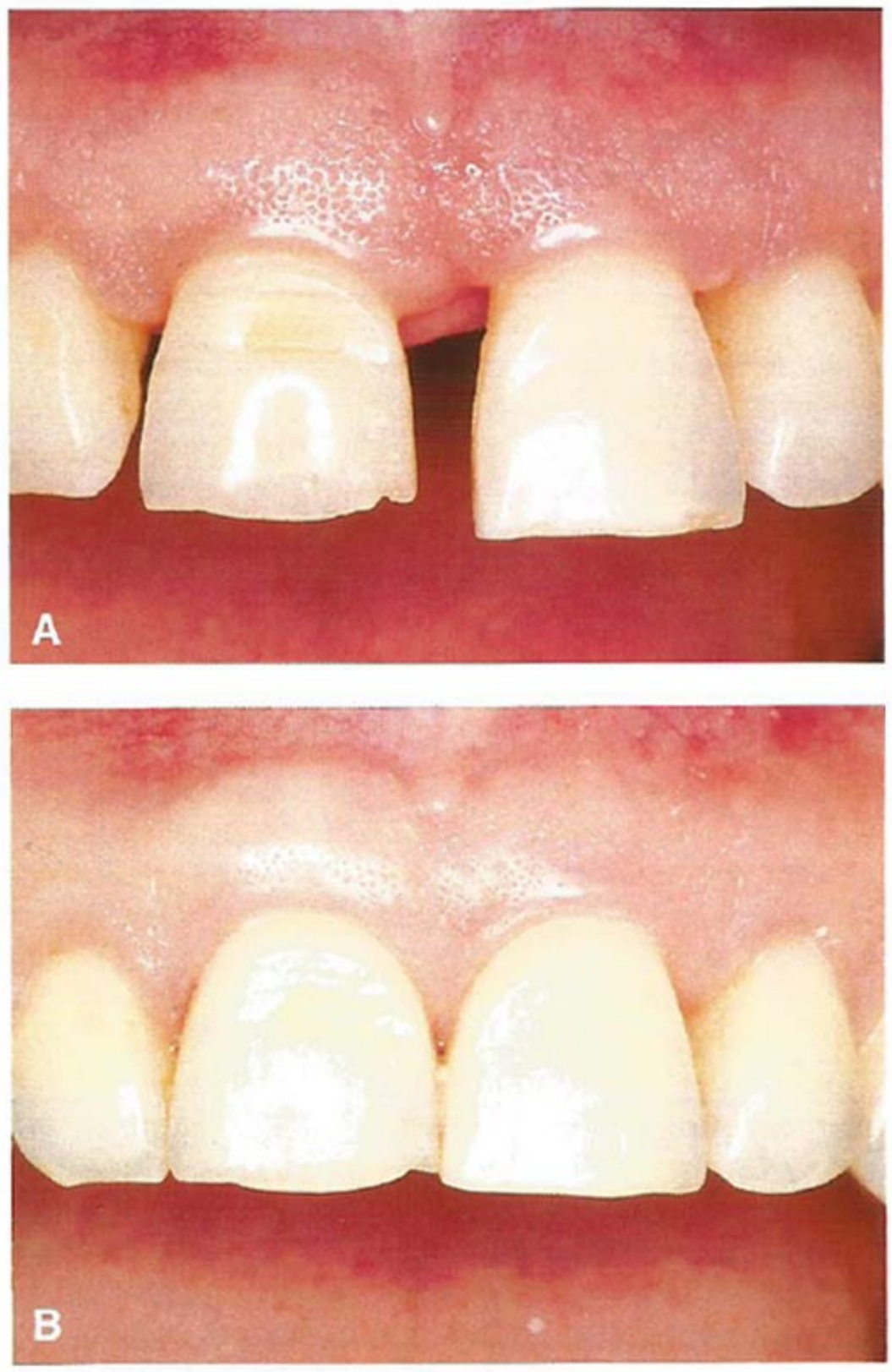

Figure 2.
Clinical documentation of patient X. ***A)*** *Clinical view before treatment.* ***B)*** *Clinical view following orthodontic treatment.*

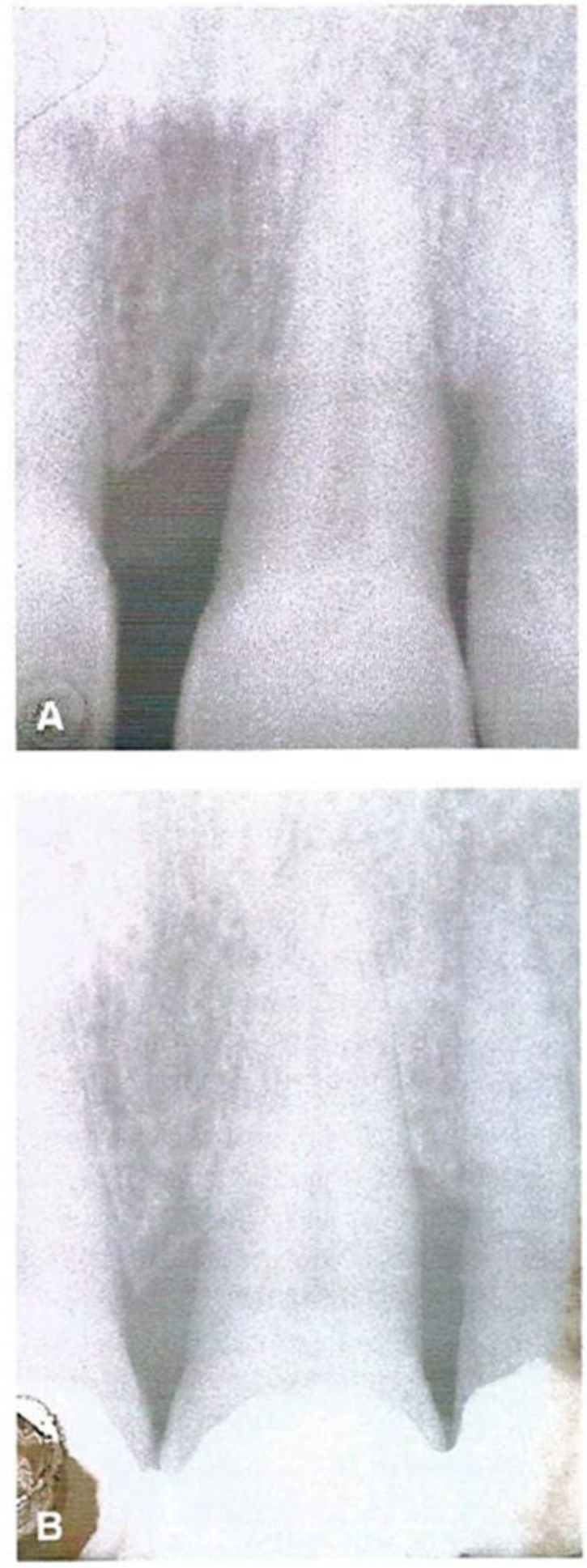

Figure 3.
Radiographic documentation of patient X. ***A)*** *Bone defect at baseline examination.* ***B)*** *Bone modifications following periodontal surgery and intrusive orthodontic therapy.*

results have been reported regarding the periodontal healing. Polson et al.,[7] in a study on monkeys, showed no connective tissue attachment gain after orthodontic movement into infrabony pocket in a healthy periodontal status. Wennström et al.,[8] in a study on dogs, reported loss of attachment level in teeth moved into infraosseous defects with periodontal inflammation. However, in both studies no intrusive mechanic was used, but the teeth were tilted or bodily moved into the defects.

On the other hand, Melsen et al.,[5] in an experimental study on monkeys, demonstrated the possibility of obtaining new attachment formation through surgical periodontal treatment and orthodontic intrusion in a situation of induced periodontal disease without infrabony pockets.

The possibility of obtaining reattachment of the periodontium after tooth movement was confirmed by Geraci et al.[23] in another experimental study on monkeys. In this work, the teeth were moved into infrabony lesions, but bodily movement, not intrusion, was performed.

Long-term human studies investigating the effect of orthodontic-periodontic therapy are limited. Re et al.,[4] in a 12-year study on 267 patients, showed the predictability of this multidisciplinary approach in the treatment of patients with severe periodontal disease and teeth migration.

Ingber[24] proposed the use of extrusive movement in order to realign the bone crest level for the treatment of migrated teeth with periodontal lesions. However,

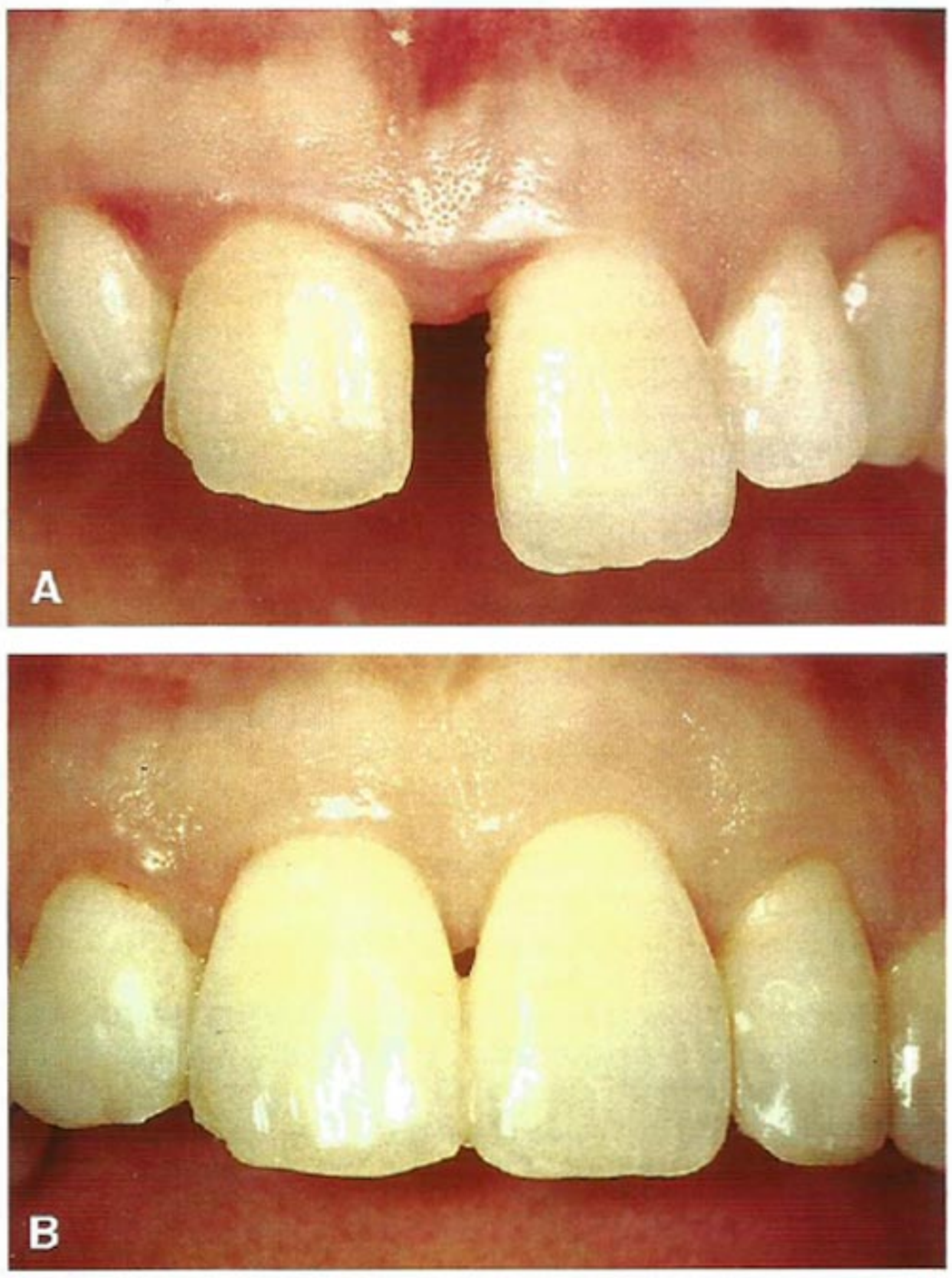

Figure 4.
Clinical documentation of patient Y. ***A)*** *Clinical view before treatment.* ***B)*** *Clinical view following orthodontic treatment.*

at the end of the therapy, endodontic and restorative treatments were necessary to reestablish a normal outline of the incisal margin at the neighboring teeth.

Therefore, intrusive movement seems to be a more effective and biologically conservative means to realign extruded teeth following periodontal disease.[6,14]

In the present study, intrusive orthodontic movement was used to realign extruded upper central incisors in patients with advanced periodontal disease and infrabony pockets. The teeth were orthodontically moved toward the bone defects. The results show a significant PD decrease and CAL gain, with a reduction of the bone defects both in horizontal and vertical radiological dimensions. Clinical attachment gain exceeded probing depth reduction, with a decrease in gingival recession probably associated to the intrusive movement.

The early start of the orthodontic movement, 7 to 10 days after surgery, seems to be effective in determining the coronal shift of the soft tissues, which is an important concern from an esthetc point of view.

The clinical results obtained in the present study do not exclude a healing by repair or regeneration of the

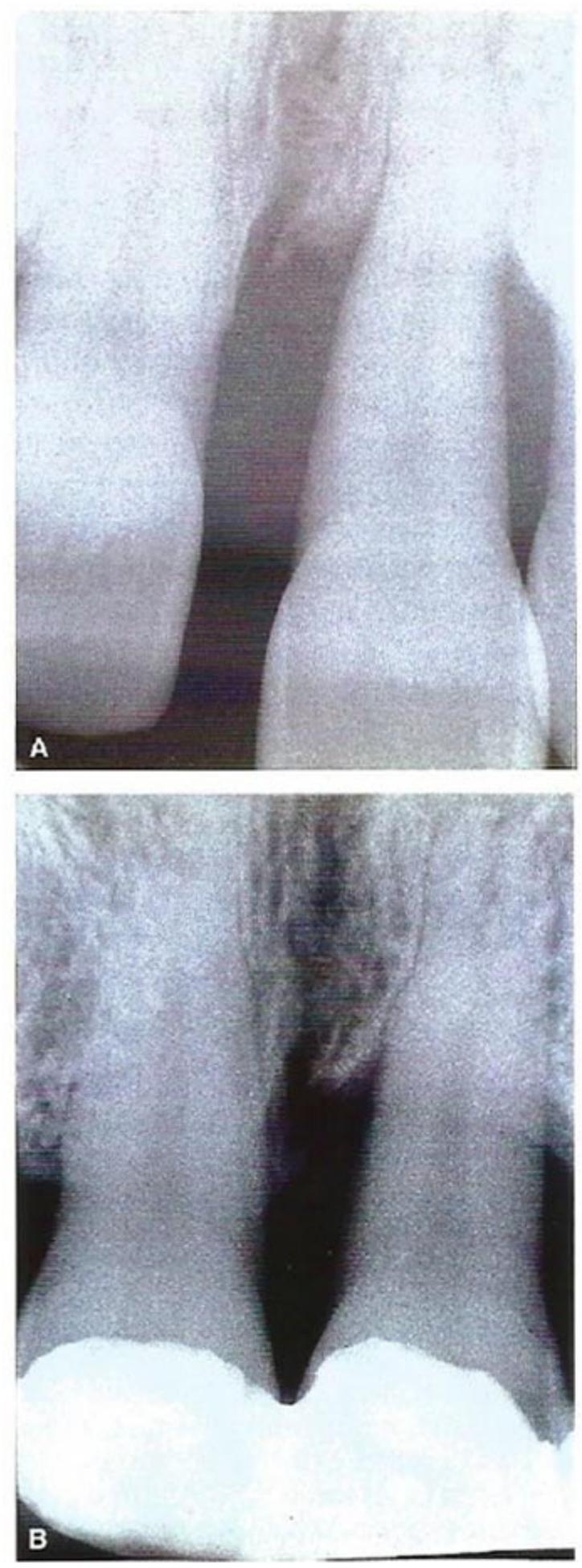

Figure 5.
Radiographic documentation of patient Y. ***A)*** *Bone defect at baseline examination.* ***B)*** *Bone modifications following periodontal surgery and intrusive orthodontic therapy.*

periodontal tissues. Roberts and Chase[25] suggested that orthodontic movement seems to be effective in increasing the mitotic activity of the periodontal ligament cells and Melsen et al.[5] showed that intrusive movements may promote new attachment formation.

It could be supposed that stretching of the periodontal ligament fibers creates a natural barrier reducing the downgrowth of the epithelial cells. Orthodontic stimulation increases the turnover of the periodontal ligament cells and improves the possibility of their repopulating the root surface.

However, these findings have not yet been confirmed by other researchers and further investigation is needed. It is unethical to perform an histologic block section in these clinical cases, or to perform a surgical reentry at the end of therapy to document how the defects repaired.

Bone fill and CAL gain obtained in this study are related in a different matter than as reported in previous investigations on the treatment of intrabony pockets in non-orthodontically moved teeth.[22] Furthermore, the radiographs were taken at the end of the orthodontic therapy when the remineralization of the bone tissue may not be completed; therefore, a higher level of bone fill will be expected at longer follow-up examination. Moreover, we must consider the limitations of a two-dimensional radiologic system used to document three-dimensional bone regeneration.

This clinical study demonstrated that it is possible to perform orthodontic intrusion toward infrabony defects of extruded incisors in patients with advanced periodontal disease, after proper periodontal therapy is performed. This combined orthodontic-periodontic treatment resulted in the realignment of the treated incisors with radiological bone fill, gain of clinical attachment level, reduction of probing depth, and gingival recession.

REFERENCES

1. Lindhe J, Svanberg G. Influence of trauma from occlusion on progression of experimental periodontitis in the beagle dog. *J Clin Periodontol* 1974;1:3-14.
2. Ericsson I, Thilander B, Lindhe J, Okamoto H. The effect of orthodontic tilting movements on the periodontal tissues of infected and non-infected dentitions in dogs. *J Clin Periodontol* 1977;4:278-293.
3. Artun J, Urbye KS. The effect of orthodontic treatment on periodontal bone support in patients with advanced loss of marginal periodontium. *Am J Orthod Dentofac Orthop* 1988;93:143-148.
4. Re S, Corrente G, Abundo R, Cardaropoli D. Orthodontic treatment in periodontally compromised patients: A 12-year report. *Int J Periodontics Restorative Dent* 2000;20:31-39.
5. Melsen B, Agerbaek N, Eriksen J, Terp S. New attachment through periodontal treatment and orthodontic intrusion. *Am J Orthod Dentofac Orthop* 1988;94:104-116.
6. Melsen B, Agerbaek N, Markenstam G. Intrusion of incisors in adult patients with marginal bone loss. *Am J Orthod Dentofac Orthop* 1989;96:232-241.
7. Polson A, Caton J, Polson AP, Nyman S, Novak J, Reed B. Periodontal response after tooth movement into infrabony defects. *J Periodontol* 1984;55:197-202.
8. Wennström JL, Lindskog-Stokland B, Nyman S, Thilander B. Periodontal tissue response to orthodontic movement of teeth with infrabony pockets. *Am J Orthod Dentofac Orthop* 1993;103:313-319.
9. Nevins M, Wise RJ. The use of orthodontic therapy to alter infrabony pockets. Part II. *Int J Periodontics Restorative Dent* 1990;10:199-207.
10. Steffensen B, Storey AT. Orthodontic intrusive forces in the treatment of periodontally compromised incisors: A case report. *Int J Periodontics Restorative Dent* 1993;13:433-441.
11. Thilander B. Infrabony pockets and reduced alveolar bone height in relation to orthodontic therapy. *Semin Orthod* 1996;2:55-61.
12. Re S, Corrente G, Abundo R, Cardaropoli D. Orthodontic movement into bone defects augmented with bovine bone mineral and fibrin sealer: A reentry case report. *Int J Periodontics Restorative Dent* 2002;22:138-145.
13. Re S, Corrente G, Abundo R, Cardaropoli D. The use of orthodontic intrusive movement to reduce infrabony pocket in adult periodontal patient: A case report. *Int J Periodontics Restorative Dent* 2002;22:365-371.
14. Cardaropoli D, Re S, Corrente G, Abundo R. Intrusion of migrated incisors with infrabony defects in adult periodontal patients. *Am J Orthod Dentofacial Orthop* 2001;120:671-675;
15. O'Leary TJ, Drake RB, Naylor JE. The plaque control record. *J Periodontol* 1972;43:38.
16. Burstone CJ. Deep overbite correction by intrusion. *Am J Orthod* 1977;72:1-22.
17. Braun S, Marcotte MR. Rationale of the segmented approach to orthodontic treatment. *Am J Orthod Dentofac Orthop* 1995;108:1-8.
18. Axelsson P, Lindhe J. The significance of maintenance care in the treatment of periodontal disease. *J Clin Periodontol* 1981;8:281-294.
19. Ramfjord SP, Morrison EC, Burgett FG, et al. Oral hygiene and maintenance of periodontal support. *J Periodontol* 1982;53:26-30.
20. Corrente G, Vergnano L, Re S, Cardaropoli D, Abundo R. Resin-bonded bridges and splints in periodontally compromised patients: A 10-year follow-up. *Int J Periodontics Restorative Dent* 2000;20:629-636.
21. Tonetti MS, Cortellini P. Cases selection and treatment consideration of guided tissue regeneration in deep infrabony defects. *Curr Opin Periodontol* 1997;4:82-88.
22. Laurell L, Gottlow J, Zybutz M, Persson R. Treatment of intrabony defects by different surgical procedures. A literature review. *J Periodontol* 1998;69:303-313.
23. Geraci TF, Nevins M, Crossetti HW. Reattachment of the periodontium following tooth movement into an osseous defect in a monkey. I. *Int J Periodontics Restorative Dent* 1990;10:184-197.
24. Ingber JS. Forced eruption. Part I. A method of treating isolated one and two wall infrabony osseous defects – Rationale and case report. *J Periodontol* 1974;45:199–206.
25. Roberts WE, Chase DC. Kinetics of cell proliferation and migration associated with orthodontically induced osteogenesis. *J Dent Res* 1981;60:174-181.

Correspondence: Dr. Giuseppe Corrente, C.so Sicilia 51, 10133 Torino, Italy. Fax: 39-011-661-17-19; e-mail: dacardar@tin.it.

Accepted for publication January 24, 2003.